

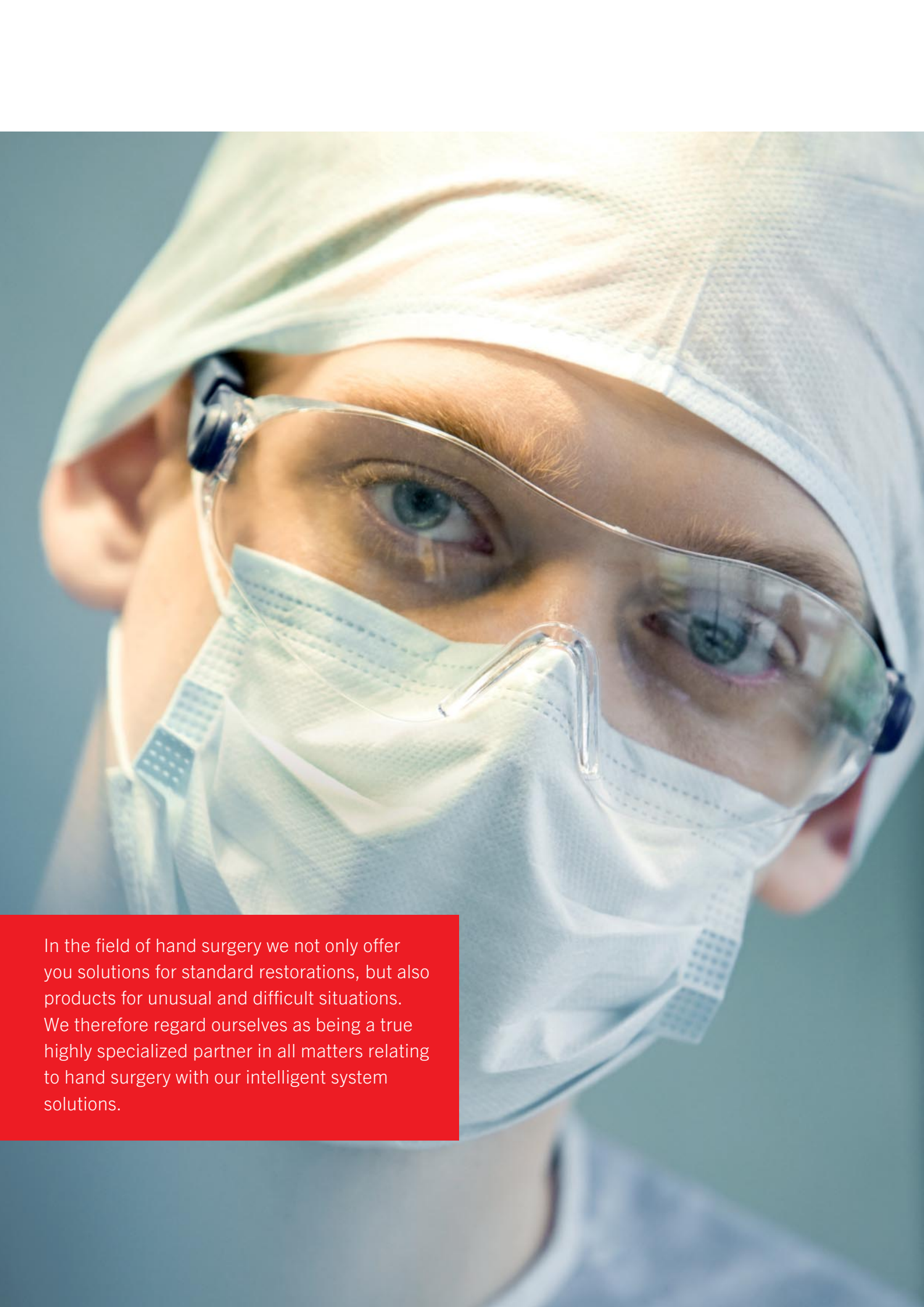---

## **HBS 2**

Improving on the tried, tested and proven



reddot design award  
winner 2011



In the field of hand surgery we not only offer you solutions for standard restorations, but also products for unusual and difficult situations. We therefore regard ourselves as being a true highly specialized partner in all matters relating to hand surgery with our intelligent system solutions.

## HBS 2

### Improving on the tried, tested and proven

After more than 100,000 successful HBS procedures worldwide, the time had come to evaluate the experiences gained and to utilize them for a new generation of headless bone screws.

A great challenge in designing the HBS 2 implants consisted in retaining the proven implant geometry while enhancing the options for individual fracture treatment.

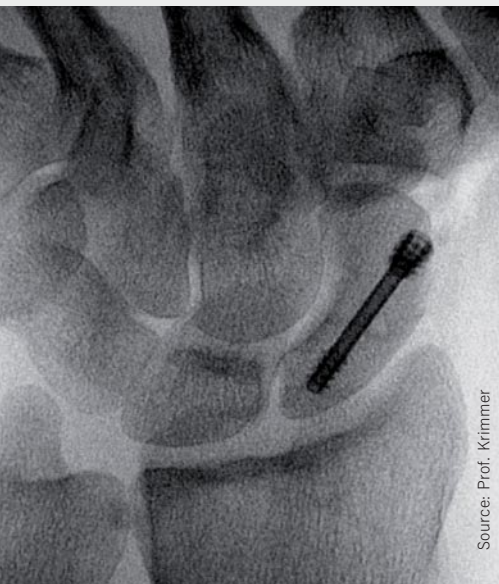
Another objective was to simplify the handling of the HBS 2 system for all parties involved – the surgeon, the assisting OR personnel and the CSSD (Central Sterilization Service Department) staff – utilizing all the technologies that are now available. By reducing the surgical steps and enhancing the ergonomics of the HBS 2 system, immediate benefits are created for patients as well as providing for substantial economic advantages.



## Table of Contents

HBS 2 product features	6-9
Indications and surgical techniques	10-35
■ Scaphoid fracture in the middle third section	
Minimally invasive palmar surgical technique	12-17
■ Scaphoid nonunion	
Open palmar surgical technique	18-25
■ Scaphoid fracture / scaphoid nonunion	
using the closing sleeve	
Open palmar surgical technique	26-29
■ DIP arthrodeses	
Open dorsal surgical technique	30-35
Product range	
■ HBS 2 implants	36-37
■ HBS 2 instruments	38-41
■ HBS 2 storage tray	42-43

## Feature, function and benefit



**HBS 2 midi**

Short thread



Long thread



Short thread



Long thread

The proven basic geometry of the HBS screws has been retained. HBS 2 screws are available in the “midi” and “mini” dimensions, non-sterile and sterile packed. In addition, users can now select among screws with different thread lengths:

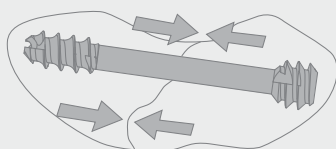
	Overall Length	Proximal Thread Length	Distal Thread Length
<b>HBS 2 midi short thread</b>	10-30 mm (1-mm steps)	3.5 mm	4-6 mm
<b>HBS 2 midi long thread</b>	20-40 mm (2-mm steps)	5.0 mm	8-13 mm
<b>HBS 2 mini short thread</b>	10-30 mm (1-mm steps)	3.0 mm	4-6 mm
<b>HBS 2 mini long thread</b>	20-40 mm (2-mm steps)	5.0 mm	8-13 mm

Moreover, all screws are self-drilling and self-tapping and the diameter of the guide wire has been increased. To facilitate explantation, the screws now feature a reverse-cutting distal thread.

## HBS 2 implants

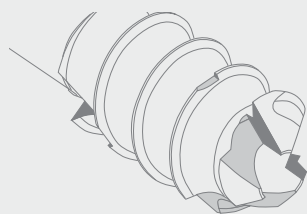
### Advantages

### Benefits



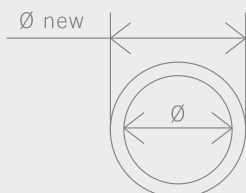
- Color-coded HBS 2 screws matching every situation

- Dependable and efficient management of all kinds of fractures, including highly comminuted ones.
- Targeted control of interfragmental compression.
- Secure bridging of the fracture gap, with best possible fit in the bone.



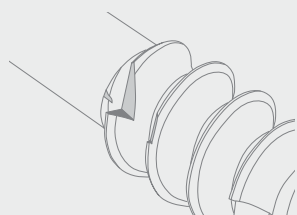
- Self-drilling and self-tapping

- Simplifies and shortens the surgical procedure.
- Saves money – no investment in disposable drills required.



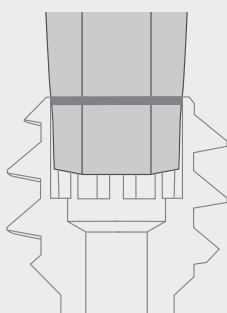
- Increased diameter of guide wire

- Even better guidance thanks to a guide wire that is almost 20% stronger.



- Reverse-cutting thread

- For easy screw explantation.




- T7 / T8 with self-retaining function

- Easy pick-up, insertion and removal of the screw.



## Feature, function and benefit



The completely redesigned instrument set has been color-coded for easy and efficient handling. No more than 3 instruments are usually required for a procedure. For exceptional cases, additional instruments (such as the closing sleeve) are also available.

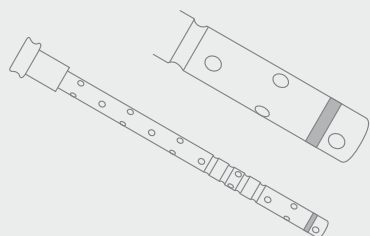
For ease of handling and storage two concepts were employed. First, the instruments are arranged according to their sequential use during the surgery. Secondly, special attention was given to optimize all aspects of instrument processing.



## HBS 2 instruments and storage tray

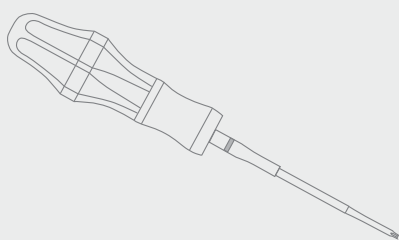
### Advantages

### Benefits



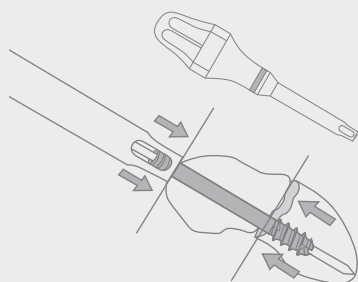
- Color-coded instruments
  - midi (magenta)
  - mini (green)

- Easy identification of the respective instruments.



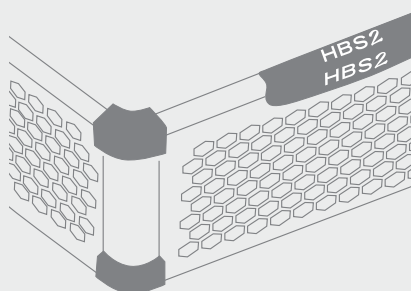
- Single-part instruments with ergonomically shaped silicone handles

- Good tactile feedback.
- No couplings that could lead to confusion.
- No parts that can get lost.



- closing sleeve

- For closing a large fracture gap remaining after reduction, or a gap remaining after bone chip implantation, before final insertion of the screw.
- Fracture fixation using the lag screw osteosynthesis principle.

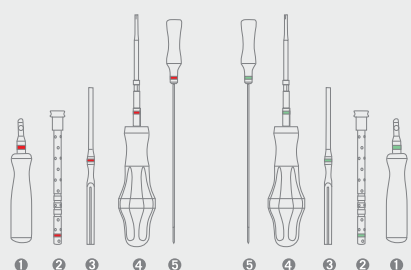


- Stainless steel storage tray in honeycomb design, combined with high-performance plastic

- High stability, but low weight.
- Large openings for superior rinsing results.
- No water residues.
- Good ergonomics.

### HBS 2 midi

### HBS 2 mini



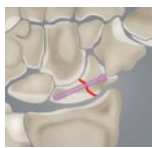- Instruments arranged according to their sequence of use during the surgical procedure

- For easy and efficient instrumentation.

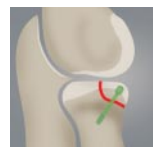## Step by step to optimal fixation

### Indications

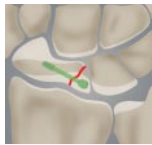
HBS 2 screws are intended for the management of intraarticular and extraarticular fractures and nonunions of small bones and fractures involving very small bone fragments, as well as for the fixation of small-joint arthrodeses.



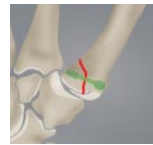Scaphoid fracture and  
scaphoid nonunion



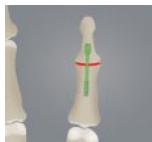Proximal radial head fracture



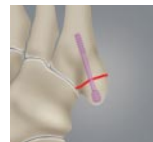Proximal pole fracture  
of the scaphoid



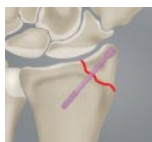Metacarpal fractures



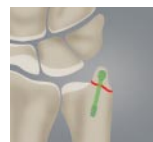
DIP arthrodeses



Metatarsal fractures



Fracture of the styloid



Fracture of the styloid

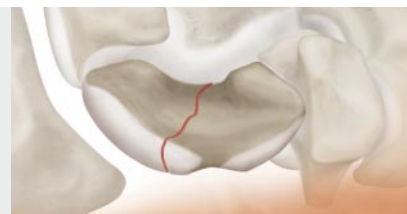


## Surgical techniques

### **Scaphoid fracture in the middle third section**

Minimally invasive palmar surgical technique  
Prof. Krimmer

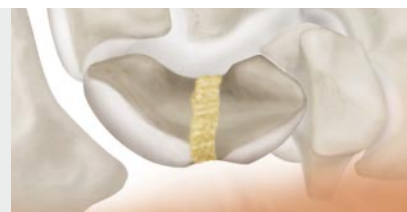
Pages 12-17



### **Scaphoid nonunion**

Open palmar surgical technique  
Prof. Krimmer

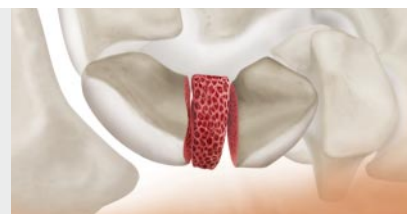
Pages 18-25



### **Scaphoid fracture/scaphoid nonunion using the closing sleeve**

Open palmar surgical technique  
Prof. Krimmer

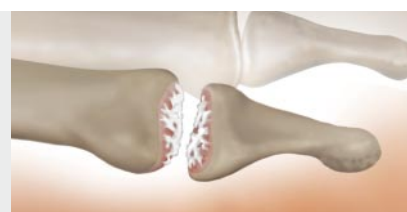Pages 26-29

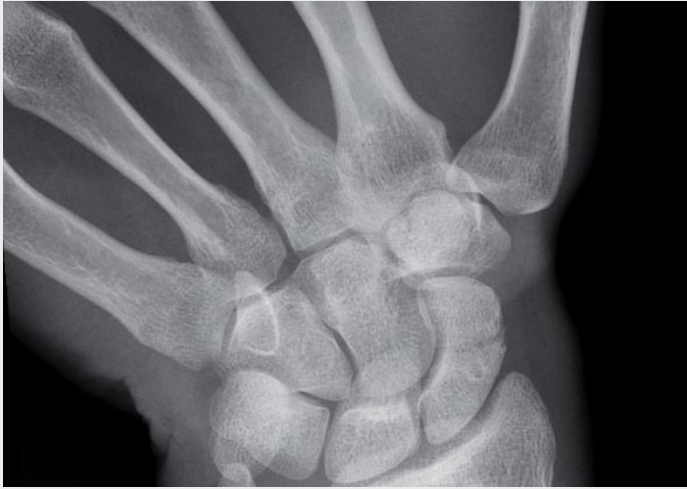

### **DIP arthrodeses**

Open dorsal surgical technique  
Prof. Krimmer

Pages 30-35





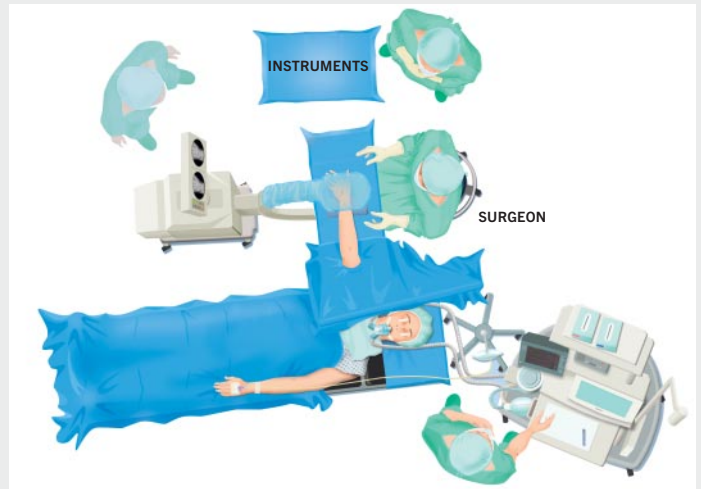
Source: Prof. Krimmer

#### Preoperative planning

In addition to standard anterior posterior and lateral X-rays, it is recommended to take radiographs with clenched fist and ulnar deviation (Stecher projection). A supplementary hyper-pronation view may be indicated as well.

High-resolution computed tomography should always be used if there is a need to clarify the condition in more detail.

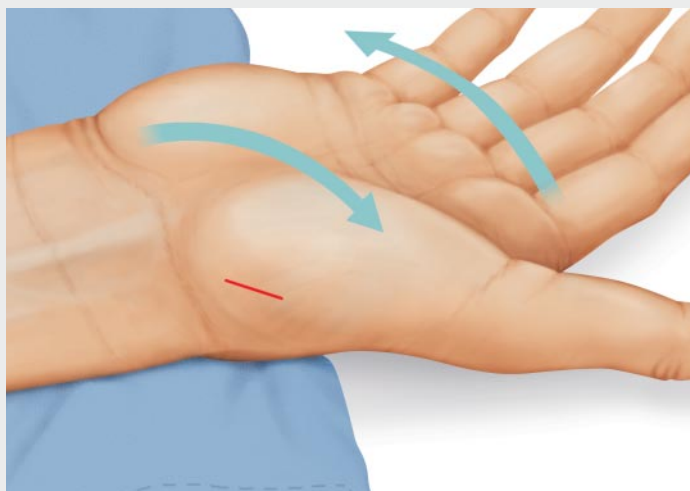
It is important to make sure that all the images are created in the longitudinal axis of the scaphoid.



#### Patient positioning – minimally invasive palmar approach

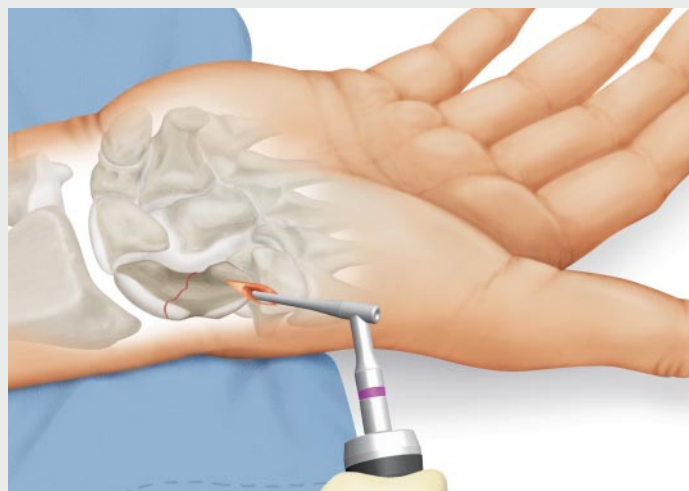The patient is placed on the back with the hand to be treated placed on the hand table in overextension and ulnar deviation and the arm exsanguinated with an above-elbow tourniquet.

The image intensifier is placed opposite the surgeon in a way that he/she can insert the guide wire from distal to proximal. This means that right-handed surgeons should be seated at the head of the table when treating the right wrist and at the foot of the table when operating on the left wrist. This setup facilitates correct guide wire insertion, as X-ray checks can be performed whenever practical.



### 1. Minimally invasive palmar approach

A short, oblique skin incision is made over the scapho-trapezio-trapezoidal (STT) joint.



### 2. Positioning the K-wire guide

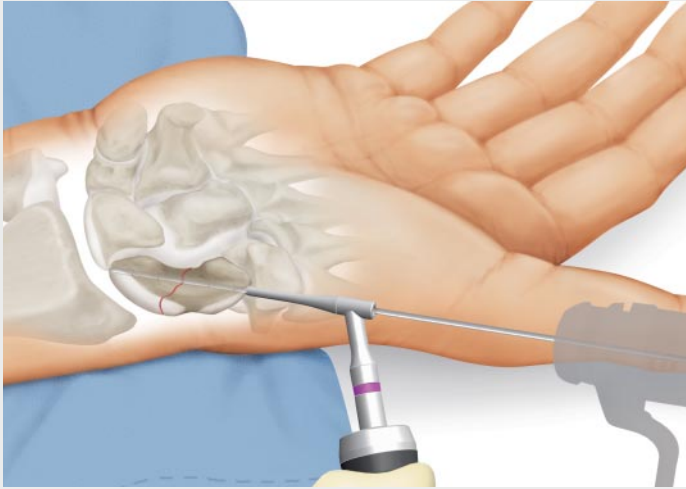The K-wire guide is put in place on the bone.

*Notice:*

*Radial positioning of the device on the distal scaphoid facilitates correct guide wire positioning.*



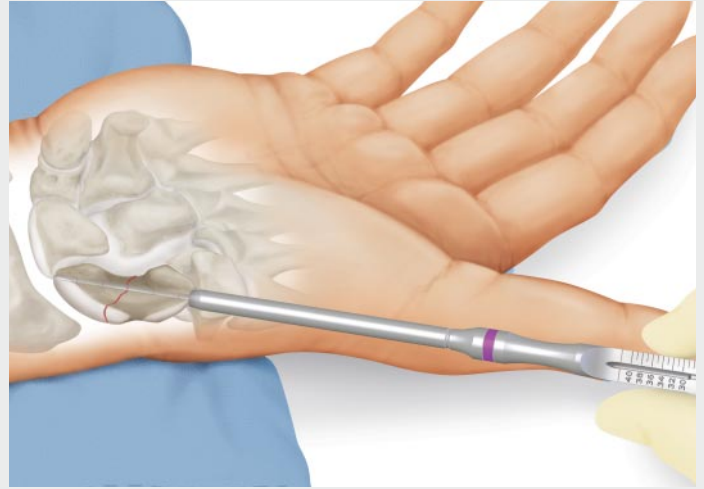
HBS 2 midi  
K-wire guide



### 3. Inserting the guide wire

Under image converter control, the guide wire is slowly inserted into the bone and optimally positioned in the longitudinal axis, centrally in both planes.

The wire tip should penetrate into – but not pierce through – the opposite cortical layer.



### 4. Determining the screw length

Following correct positioning of the guide wire, the K-wire guide is removed and the depth gauge pushed over the projecting end of the guide wire all the way down to the bone to determine the required screw length.

The length of the inserted guide wire section can now be read from the scale.

Depending on the width of the fracture gap, approx. 2 to 4 mm must be subtracted from the indicated value for correct determination of the screw length.

Screw lengths usually range between 22 and 26 mm.



HBS 2 midi  
K-wire dispenser,  
Ø 1.1 mm



HBS 2 midi  
guide wire,  
Ø 1.1 mm, 125 mm

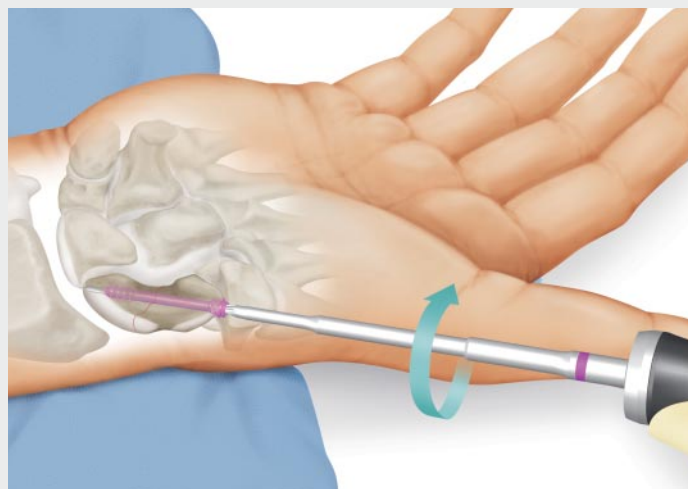
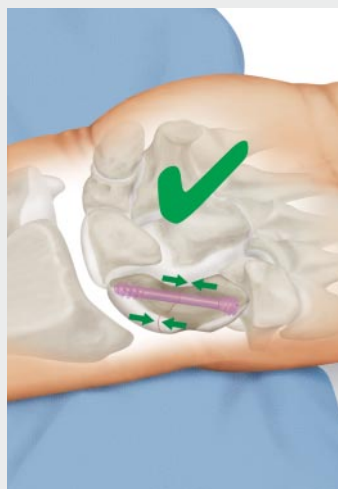
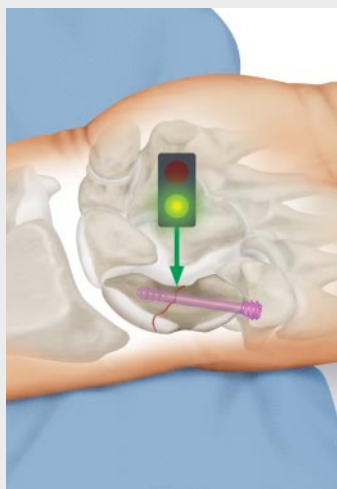
HBS 2 midi  
K-wire guide



HBS 2 midi  
depth gauge





#### 5. Selecting the screw

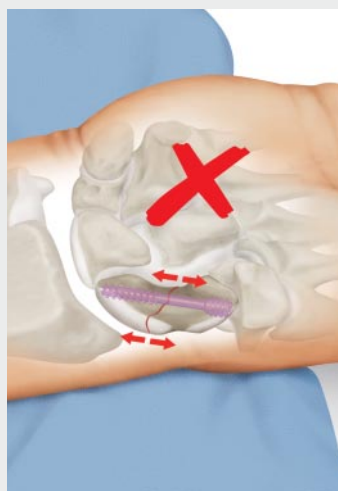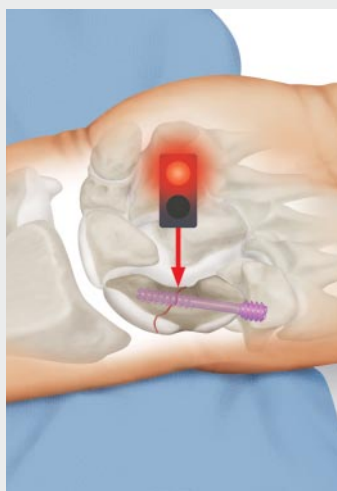
An essential parameter for screw selection is the position of the fracture gap.

It is important to ensure that the distal thread of the HBS 2 screw has completely crossed the fracture gap before the short proximal thread enters the bone. This is the only way to achieve interfragmental compression.

The above illustration (green “traffic light” symbol) shows how a correctly selected HBS 2 screw works, whereas the lower illustration (red “traffic light” symbol) shows what happens when selecting a screw with a thread that is too long.

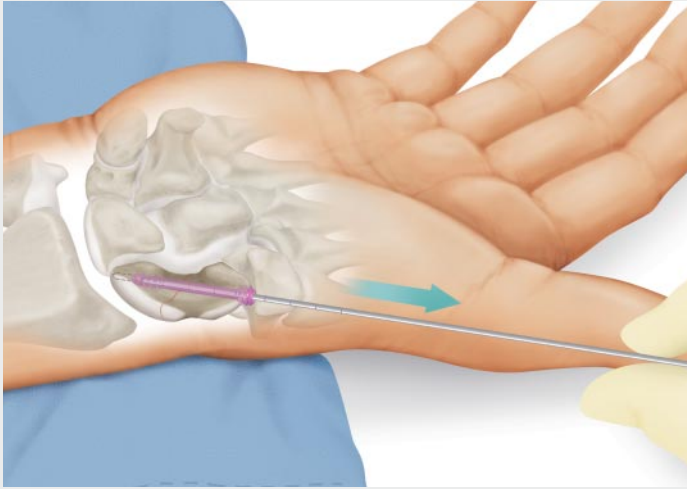
#### 6. Inserting the screw

A screw of the correct length is now picked from the rack with the screwdriver, to be implanted via the guide wire.



HBS 2 midi  
T8 screwdriver

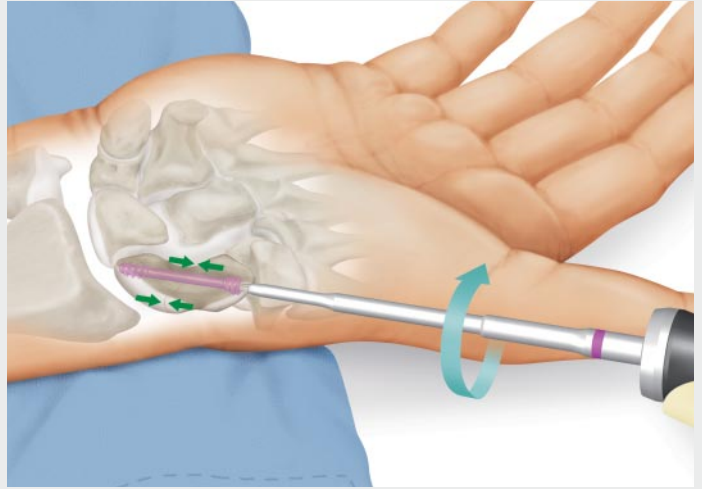




#### 7. Removing the guide wire

Once the distal screw thread has crossed the fracture gap (check by X-ray), the guide wire should be removed in order to prevent the screw from canting on the wire.

The fracture gets compressed as soon as the proximal thread starts taking hold in the bone. Compression is clearly defined by two parameters: the length of the proximal thread and the different thread pitches.

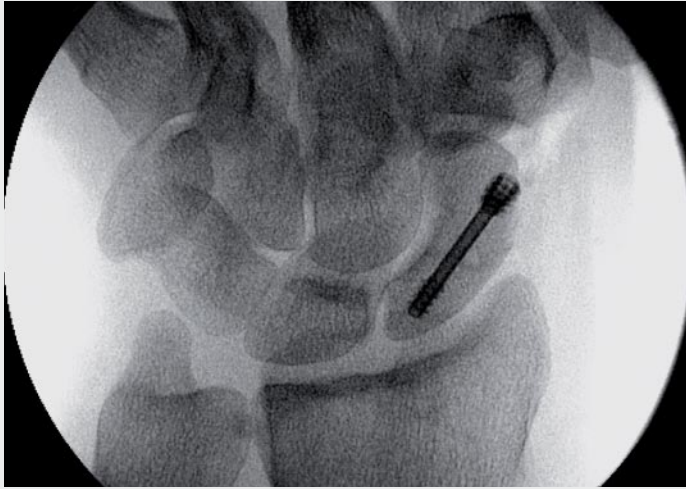


#### 8. Final position of the screw

The screw is now screwed in by one or two additional turns to insert the proximal thread to a point slightly below the bone surface.



HBS 2 midi  
T8 screwdriver



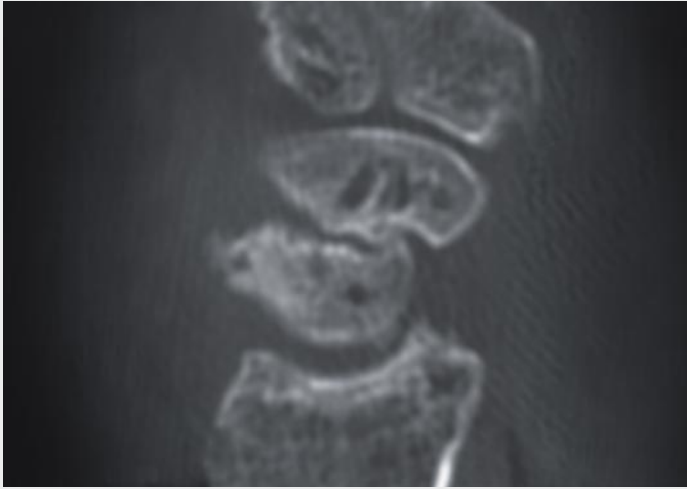
Source: Prof. Krimmer

#### **Follow-up treatment**

Depending on postoperative pain, a cushioning elastic bandage is applied for 2 weeks. A palmar splint can alternatively be used for 1 to 2 weeks in case of more pronounced pain symptoms.

The first postoperative radiographic check is carried out after 6 weeks, with X-rays taken in the AP and lateral beam paths and in the Stecher projection.

An additional high-resolution CT scan in the longitudinal axis of the scaphoid is recommended in cases of doubt.



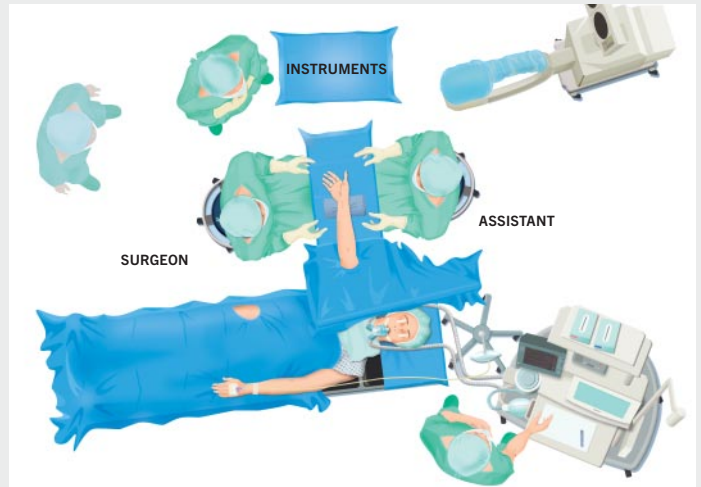
Source: Prof. Krimmer

### Preoperative planning

In addition to standard AP and lateral X-rays, it is recommended to take radiographs with clenched fist and ulnar deviation (Stecher projection). A supplementary hyperpronation view image may be indicated as well.

High-resolution computed tomography should always be used if there is a need to clarify the condition in more detail.

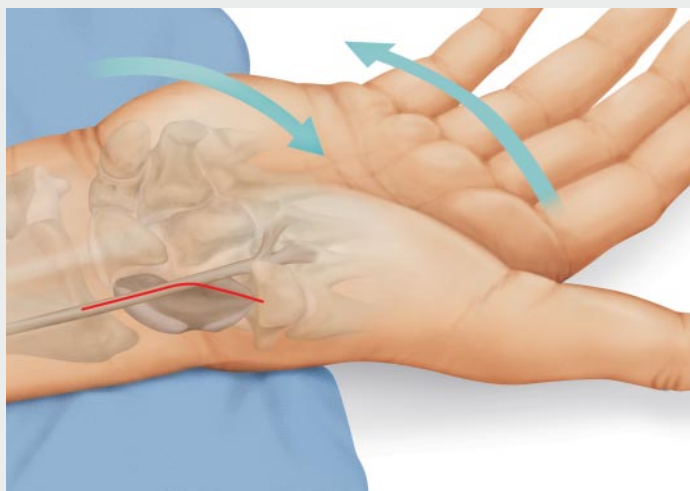
It is important to make sure that all the images are created in the longitudinal axis of the scaphoid.



### Patient positioning – open palmar approach

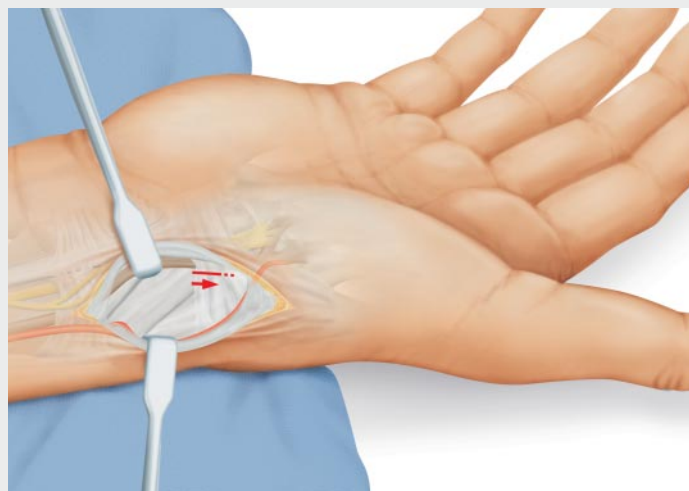
The patient is placed on the back with the hand to be treated placed on the hand table in overextension and ulnar deviation and the arm exsanguinated with an above-elbow tourniquet.

If a corticocancellous bone chip needs to be harvested from the iliac crest, the pelvis of the patient must also be prepared and covered for the intervention.



### 1. Open palmar approach

Starting at the scaphoid tubercle, a slightly curved skin incision is made along the FCR tendon.

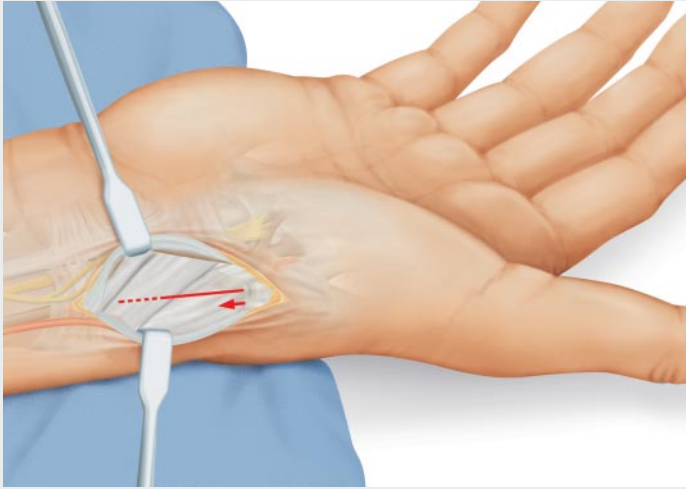


### 2. Open palmar approach

The sheath of the flexor carpi radialis tendon is exposed and opened and the FCR tendon is subsequently retracted ulnarly.

The incision is extended distally up to the superficial palmar branch of the radial artery.

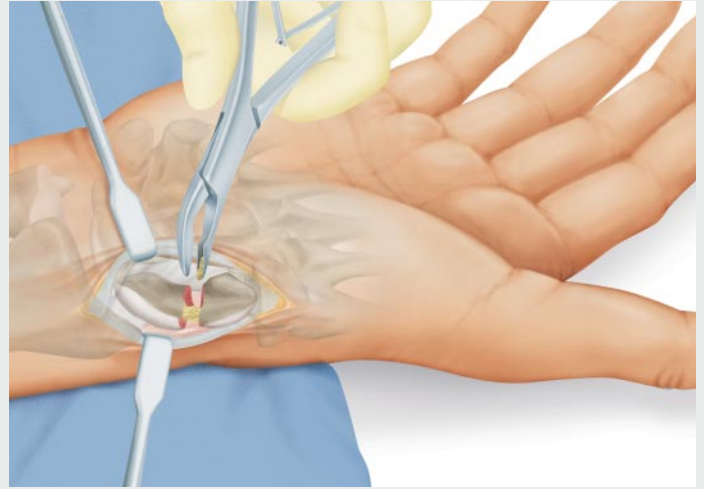
If necessary, this branch of the radial artery must be ligated.



### 3. Open palmar approach

Thereafter, the STT joint is localized distally and opened transversely.

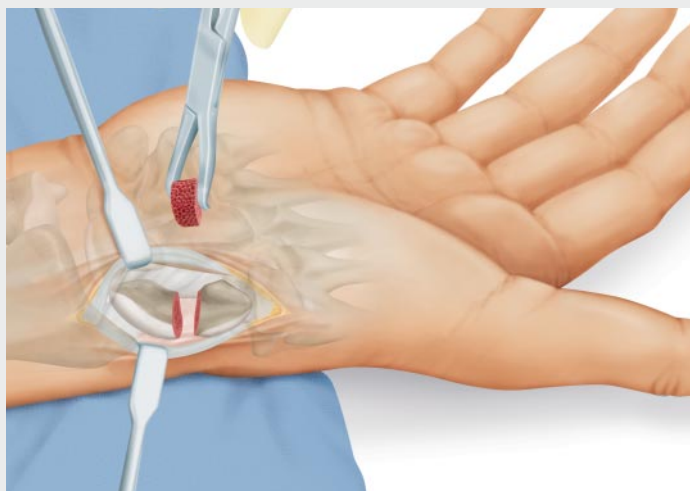
The lateral capsule-ligament structures should be preserved, as they are mainly responsible for arterial blood supply to the scaphoid.



### 4. Removing the nonunion

The nonunion is resected widely, usually with a bone rongeur. A chisel may be used if the bone is exceptionally hard.

The resection should be performed to the point where cancellous bone structure becomes visible.



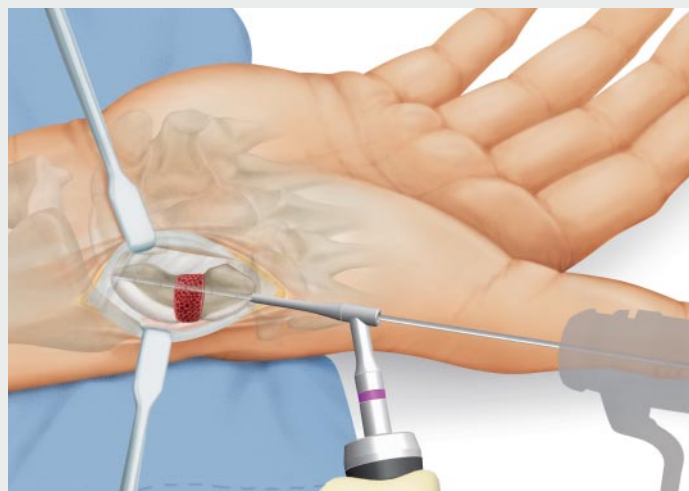### 5. Implanting a bone chip

Once the nonunion has been removed, a corticocancellous bone chip is harvested from the iliac crest. This is preferably done with the iliac-crest cancellous bone graft mill (item no. 23-190-05-07 or 23-190-06-07). Compared with conventional methods, this not only shortens intervention times, but significantly reduces morbidity as well.

This method offers the advantage of gaining a compressed and thus stable cancellous bone graft that allows both cortical layers to be removed. This, in turn, supports vascularization during the healing phase.

The harvested bone chip can now be implanted. Where a hump-back deformity is involved, make sure that reduction of the distal fragment goes hand in hand with the anatomical reconstruction of the scaphoid.

In cases where the defect is very large, stabilization with a temporary K-wire may be helpful. To prevent collision with the guide wire, the temporary K-wire should preferably be inserted on the ulnar side.




### 6. Inserting the guide wire

Under image converter control, the guide wire is slowly inserted into the bone and optimally positioned in the longitudinal axis, centrally in both planes.

The wire tip should penetrate into – but not pierce through – the opposite cortical layer.



HBS 2 midi  
K-wire dispenser,  
Ø 1.1 mm

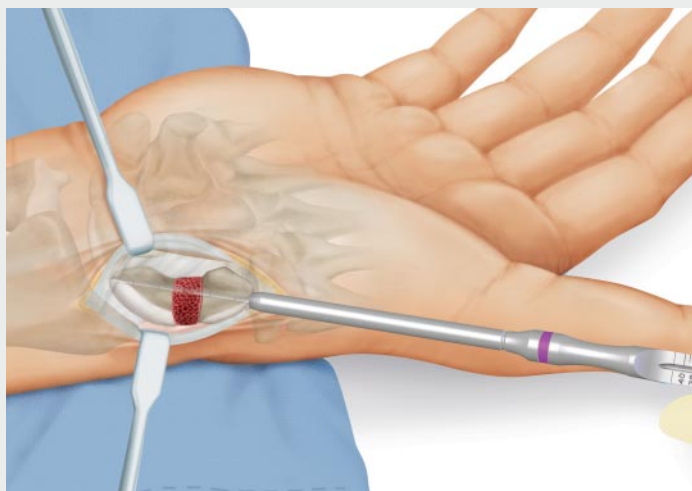


HBS 2 midi  
guide wire,  
Ø 1.1 mm, 125 mm



HBS 2 midi  
K-wire guide





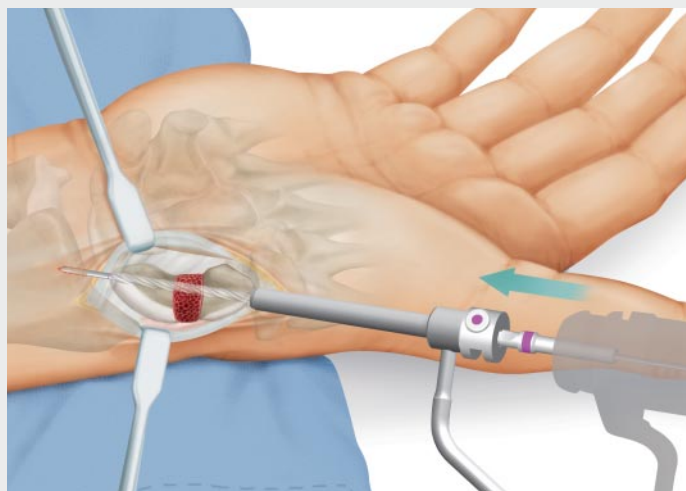
#### 7. Determining the screw length

Following correct positioning of the guide wire, the K-wire guide is removed and the depth gauge pushed over the projecting end of the guide wire all the way down to the bone to determine the required screw length.

The length of the inserted guide wire section can now be read from the scale.

To determine the screw length correctly, approx. 2 mm must be subtracted from the indicated value, provided the cortico-cancellous bone chip has been inserted by press-fit.

Screw lengths usually range between 22 and 26 mm.



#### 8. Pre-drilling

When treating older scaphoid nonunions involving a sclerosed proximal fragment, we recommend careful pre-drilling of the screw hole under image converter control using the cannulated drill bit without stop in conjunction with the guide wire. Pre-drilling is indicated because the bone structure is particularly hard in this case.

As illustrated above, there is the alternative option of using the cannulated drill bit with stop in conjunction with the soft tissue sleeve for pre-drilling the hole. In this case, the previously measured length is set on the drill bit using the depth stop. Thereafter, the bit is inserted all the way along the guide wire under image converter control until the stop hits the soft tissue sleeve.

*Notice:*

*To prevent the guide wire from dropping out after drilling, you may push it forward into the distal radius before starting the process. Following this working step, the wrist should then no longer be moved in order to prevent wire breakage.*



HBS 2 midi  
depth gauge

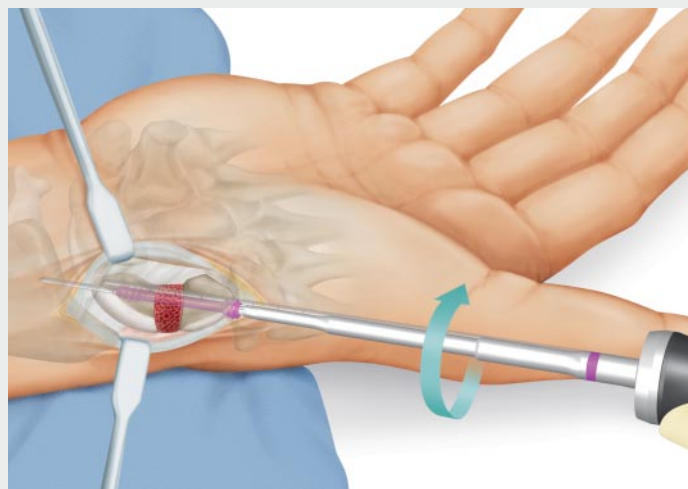
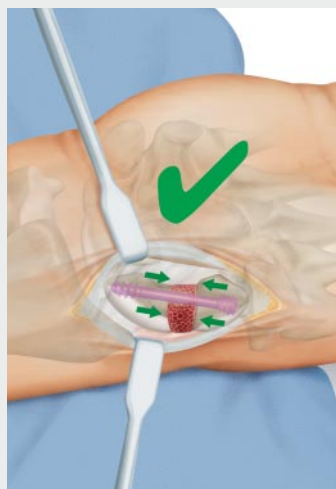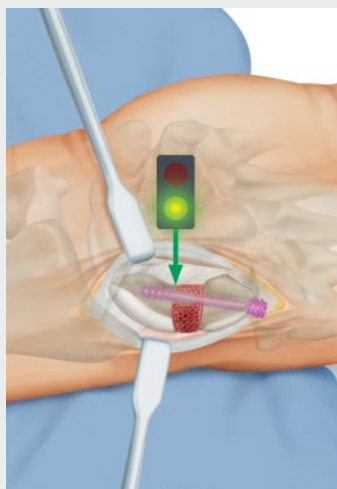


HBS 2 midi  
soft tissue sleeve



HBS 2 midi  
twist drill with stop, cannulated,  
AO attachment, Ø 2.3 / 1.1 mm





### 9. Selecting the screw

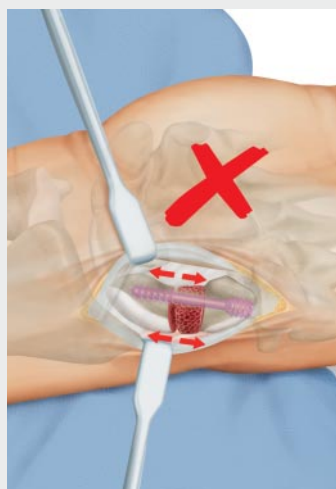
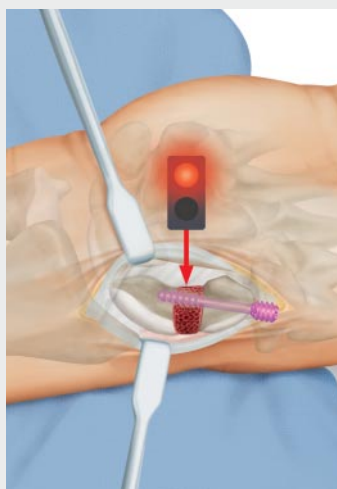
An essential parameter for correct screw type selection is the position of the nonunion or the bone chip.

It is important to ensure that the distal thread of the HBS 2 screw has completely crossed the nonunion zone before the short proximal thread enters the bone. This is the only way to achieve interfragmental compression.

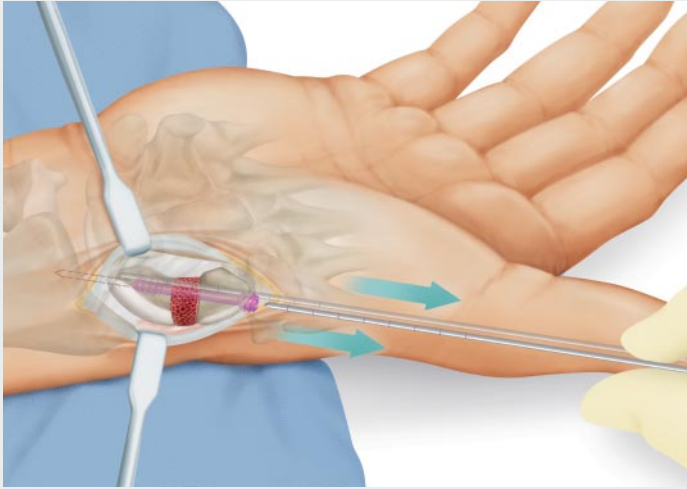
The above illustration (green “traffic light” symbol) shows how a correctly selected HBS 2 screw works, whereas the lower illustration (red “traffic light” symbol) shows what happens when selecting a screw with a thread section that is too long.

### 10. Inserting the screw

A screw of the correct length is now picked from the rack with the screwdriver, to be implanted via the guide wire.



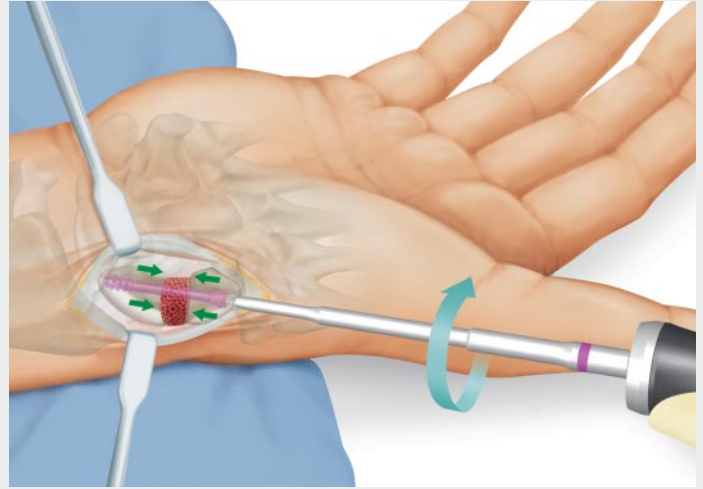
HBS 2 midi  
T8 screwdriver



#### 11. Removing the guide wire

Once the distal screw thread has crossed the bone chip (check by X-ray), the guide wire should be removed in order to prevent the screw from canting on the wire. If used, the anti-rotation wire is now removed as well.

The fracture gets compressed as soon as the proximal thread starts taking hold in the bone. Compression is clearly defined by two parameters: the length of the proximal thread and the different thread leads.

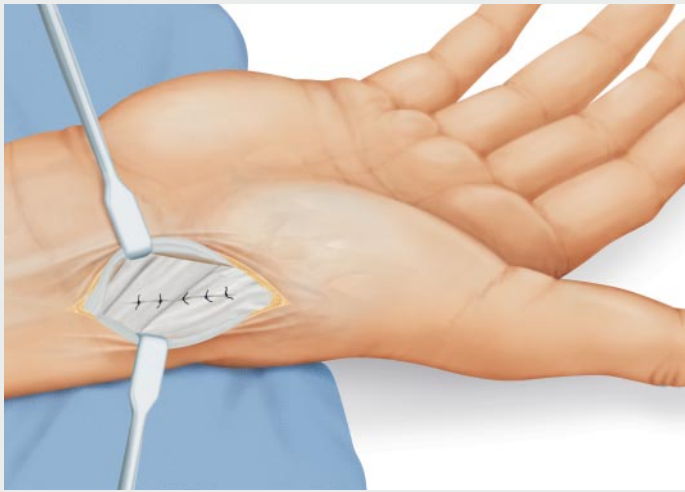


#### 12. Final position of the screw

The screw is now screwed in by one or two additional turns to insert the proximal thread to a point slightly below the bone surface.

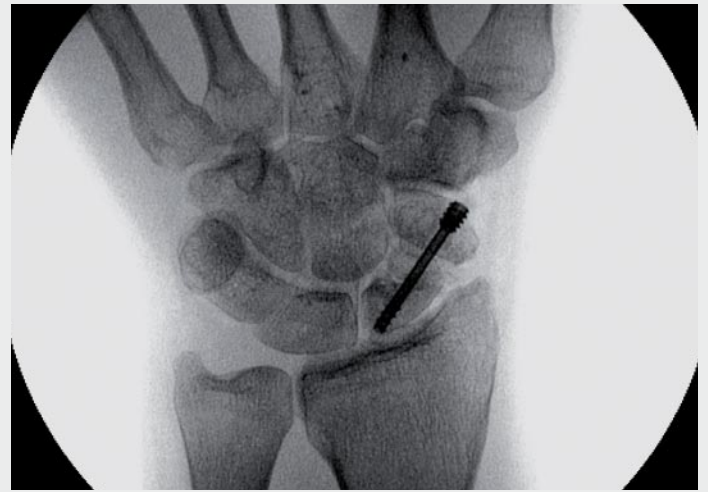

HBS 2 midi  
T8 screwdriver



### 13. Closing the wound

The wound should be carefully closed, with exact adaptation of the capsular-ligamental structure and separate closure of the anterior layer of the sheath of the FCR tendon to prevent scarring and resulting loss of motion.



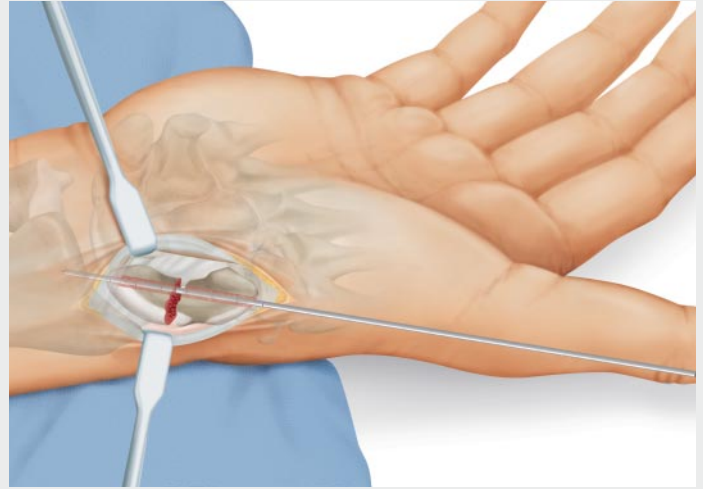
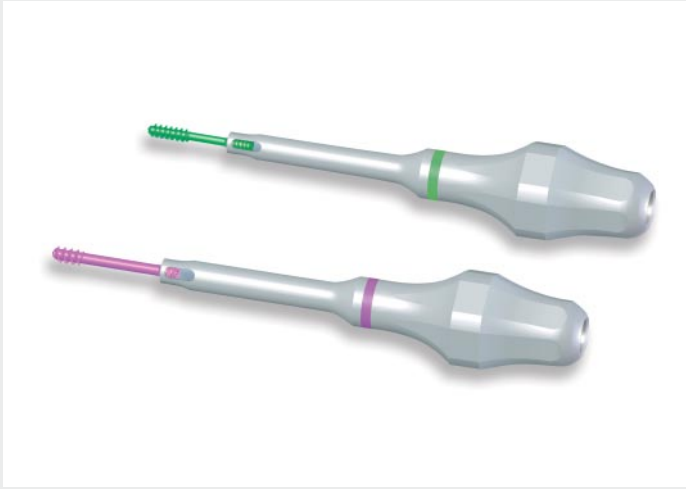Source: Prof. Krimmer

### Follow-up treatment

A plaster cast is used to immobilize the wrist for 6 weeks after the operation.

The first postoperative radiographic check is carried out after 6 weeks, with X-rays taken in the AP and lateral beam paths and in the Stecher projection.

An additional high-resolution CT scan in the longitudinal axis of the scaphoid is recommended in cases of doubt.



**1. Closing the fracture gap or the nonunion zone**

In cases where the fracture gap is particularly large or the nonunion area still leaves a gap after bone chip implantation, we recommend closing the gap in a first step using the closing sleeve.

The HBS 2 screw connects to the closing sleeve via the proximal thread, the thread creating a flush fit with the tip of the closing sleeve.

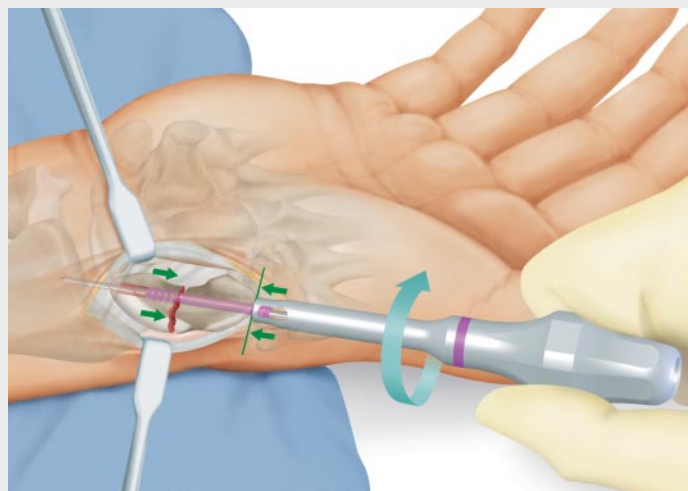
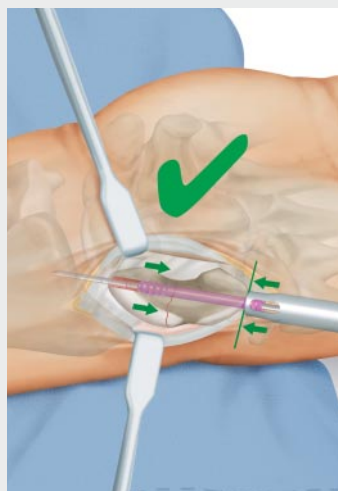
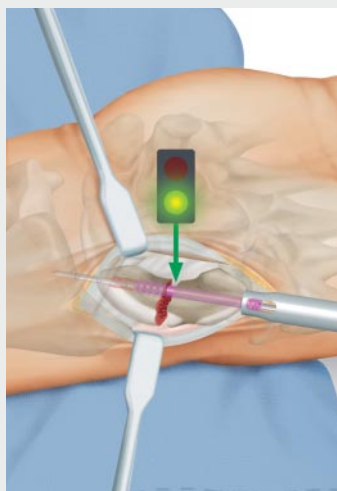
*Notice:*

*The same instrument is available for the HBS 2 mini system as well.*

**2. Inserting the guide wire, determining the screw length, pre-drilling the hole**

When using the closing sleeve, guide wire insertion and screw length determination are still done in the same way as described on pages 21 and 22.

To minimize resistance and make screw insertion with the closing sleeve as easy as possible, we recommend pre-drilling the hole as described on page 22.

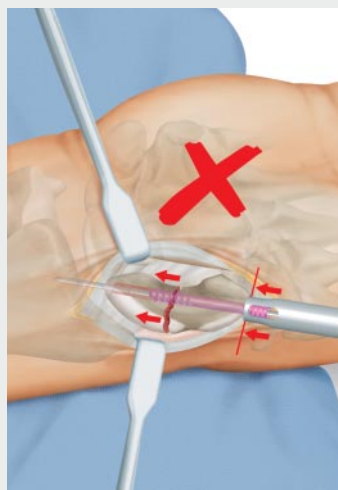
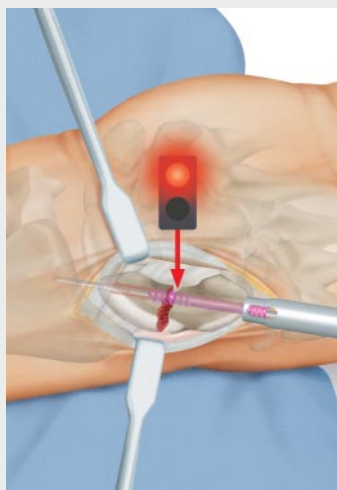


### 3. Selecting the screw

An essential parameter for correct screw type selection is the position of the fracture gap or the nonunion zone.

When using the closing sleeve, it is all the more important to ensure that the distal thread of the HBS 2 screw has completely crossed the fracture gap or the nonunion zone before the short proximal thread enters the bone. In fact, this is the only way to close the remaining gap in a first step and achieve interfragmental compression thereafter.

The above illustration (green “traffic light” symbol) shows how a correctly selected HBS 2 screw works in conjunction with the closing sleeve, whereas the lower illustration (red “traffic light” symbol) shows what happens when selecting a screw with a thread section that is too long.



### 4. Lag screw osteosynthesis with the closing sleeve

As the closing sleeve uses the scaphoid bone as a support, thus creating an abutment, it is possible to close the remaining gap under visual control by utilizing the lag screw osteosynthesis principle.

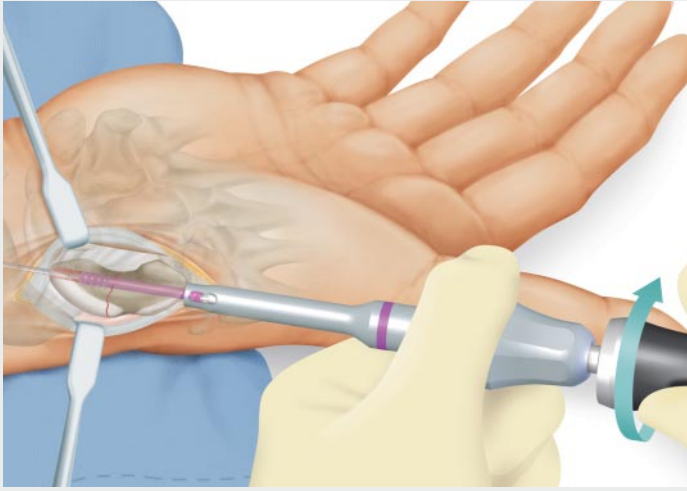
*Notice:*

*This technique is ideal for using the lag screw principle – with the associated advantage of a countersunk screw head – in other places as well.*



HBS 2 midi  
closing sleeve

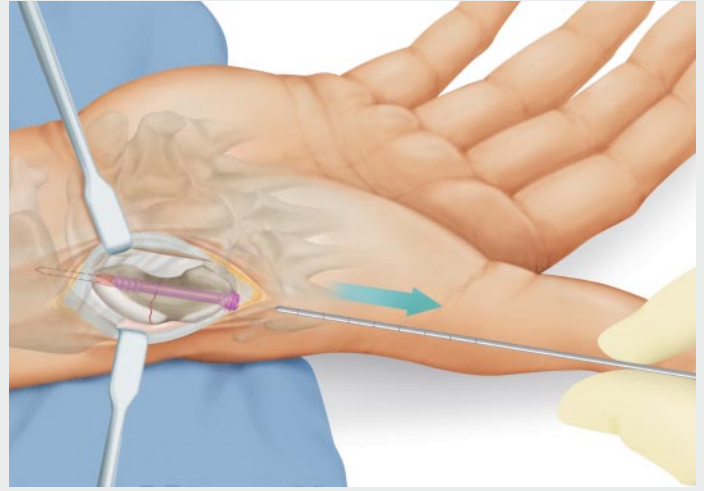




#### 5. Inserting the screw

Upon closing the gap with the closing sleeve, the screwdriver is inserted into the cannulation of the instrument to bring the HBS 2 screw into its final position.

Once the proximal thread takes hold in the scaphoid, interfragmental compression is applied in a controlled way, clearly defined by the length of the proximal thread and the different thread pitches.



#### 6. Removing the guide wire

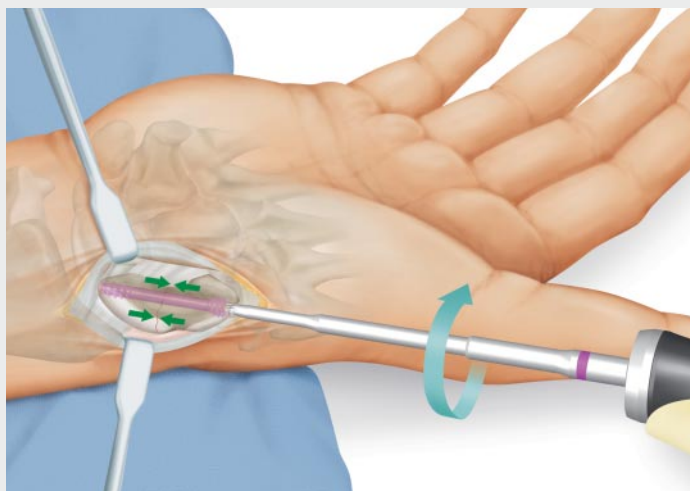
As soon as the proximal thread takes hold in the bone, the guide wire and the closing sleeve should be removed.



HBS 2 midi  
closing sleeve



HBS 2 midi  
T8 screwdriver



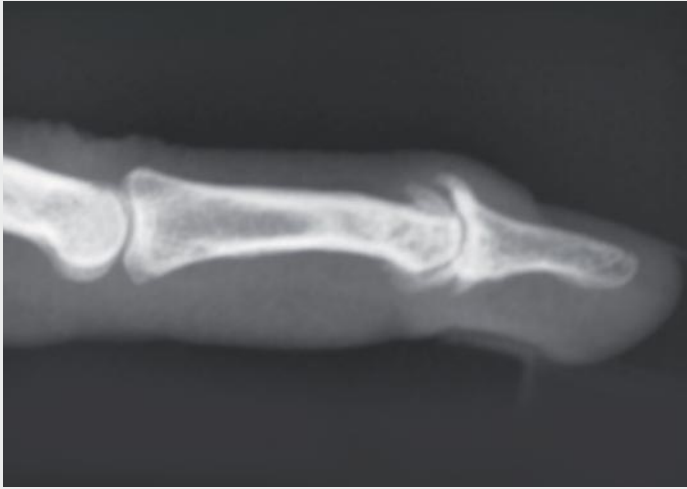#### 7. Final position of the screw

The screw is now screwed in by one or two additional turns to insert the proximal thread to a point slightly below the bone surface.



HBS 2 midi  
T8 screwdriver

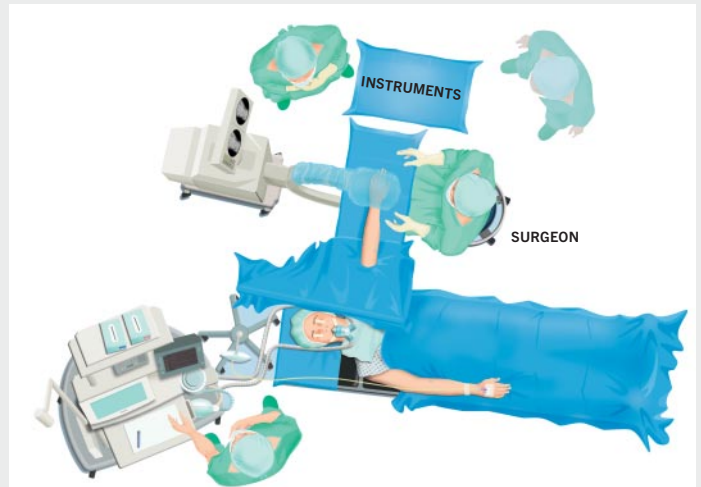




Source: Prof. Krimmer

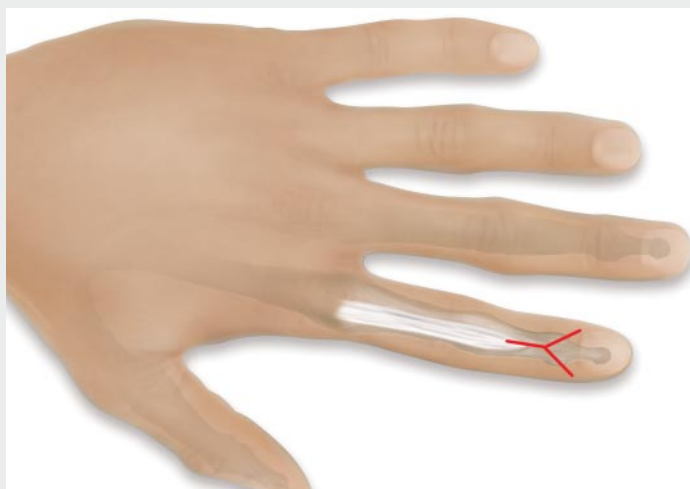
#### Preoperative planning

Standard exposures are made with a P/A and lateral beam.



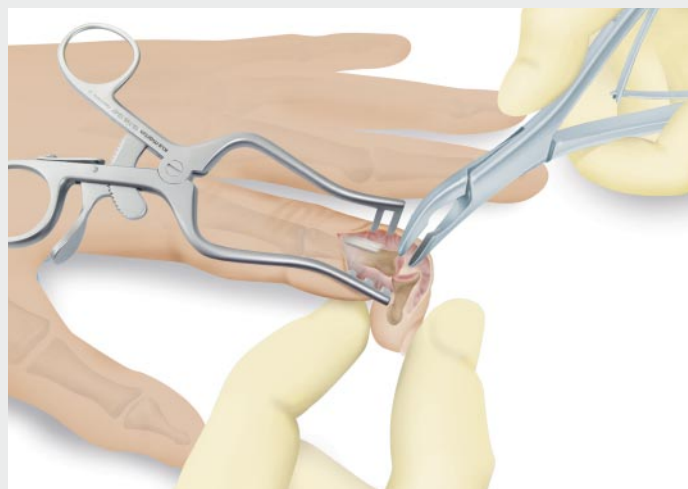
#### Patient positioning – open dorsal approach

The patient is placed on the back with the hand to be treated placed on the hand table in the pronation position and the arm exsanguinated with an above-elbow tourniquet.



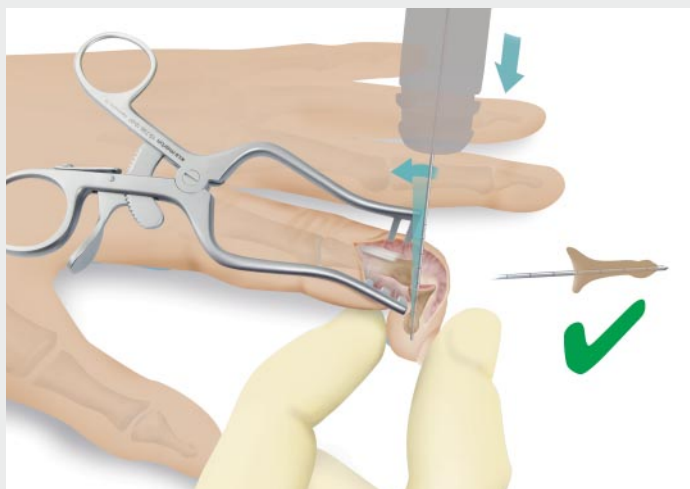
### 1. Dorsal approach

A dorsal, Y-shaped skin incision is made above the distal interphalangeal joint. Then the extensor tendon is transected and the collateral ligaments are released proximally.



### 2. Preparation of the bone

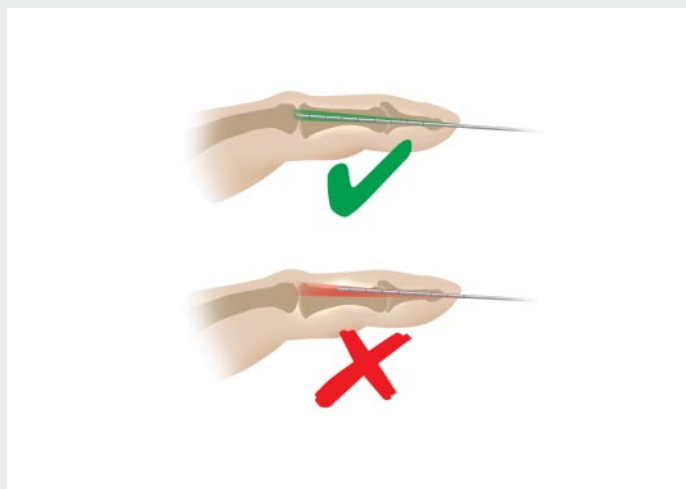
Cartilage is sparingly removed from the articular surfaces of the distal interphalangeal joint using the cup and cone technique. That creates congruent concave/convex contact surfaces to optimize positioning of the arthrodesis. Dorsal osteophytes are removed. Pre-existing angulatory deformities must be compensated by the resection.



### 3a. Introduction of the guide wire

A double-pointed guide wire is introduced to the distal phalanx from proximal to distal, whereby the point of entry is more toward the base (transition from the middle third to the palmar third). That is followed by reduction.

Generally speaking, angulation should be oriented toward the palmar side of the phalanx in order to keep the guide wire subsequently introduced to the middle phalanx in an intraosseous position throughout. That avoids the risk of the guide wire and screw running up against the cortical bone of the middle phalanx from inside.

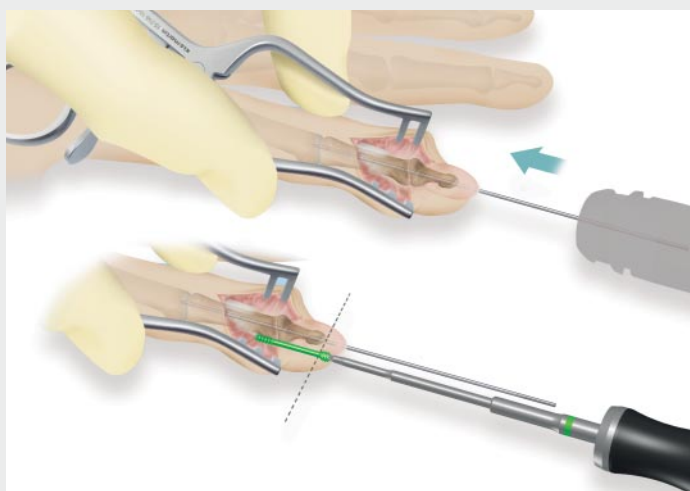


### 3b. Introduction of the guide wire

The green checkmark indicates correct, central positioning of the guide wire. The red cross indicates incorrect positioning of the guide wire – the wire runs up against the cortical bone of the middle phalanx.



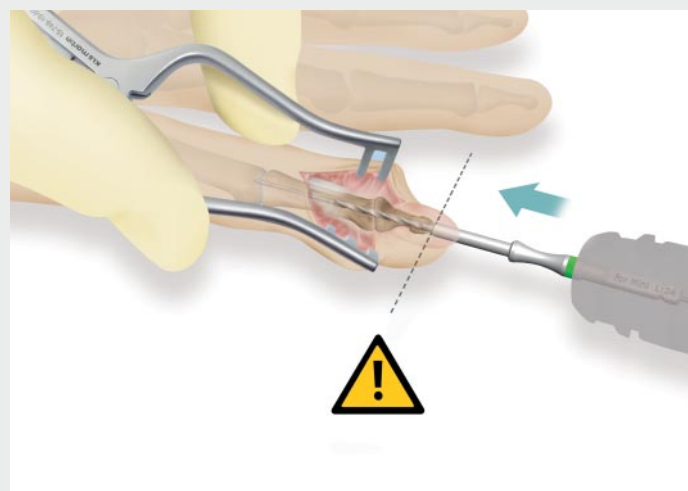
HBS 2 midi guide wire,  
double-pointed,  
Ø 0.9 mm, 120 mm



#### 4. Introduction of the guide wire

Following orientation of the distal phalanx relative to the middle phalanx, the guide wire is introduced to the middle phalanx from distal to proximal via the existing stitch channel under fluoroscopic control. The wire must be introduced centrally and neither the wire nor the screw to be implanted later may run up against the cortical bone of the middle phalanx from inside.

The selection of screw depends on the position of the articular cavity. The distal thread of the HBS 2 screw must have completely crossed the articular cavity before the short proximal thread grips the bone. That is the only way in which interfragmentary compression can be achieved. For management of DIP arthrodeses we recommend screw lengths 22, 24, and 26 mm.



#### 5. Pre-drilling

Since the bone structure is particularly hard, for the management of DIP arthrodeses it is absolutely essential to perform pre-drilling. For this purpose the step drill specially developed for this method of management can be used. It is used in conjunction with the 4 mm shorter screws. When using the step drill, drilling is conducted until the step has been reached, thus ensuring that pre-drilling is performed at least 4 mm over the length of the screw to be implanted later. That avoids the risk of the screw running up against hard, cortical or even sclerotic bone and, in the worst case, breaking.

Alternately, the cannulated HBS 2 mini drill with stop can be used in conjunction with the tissue protection sleeve. The drill is now introduced along the guide wire under fluoroscopic control until the depth stop is on the tissue protection sleeve.



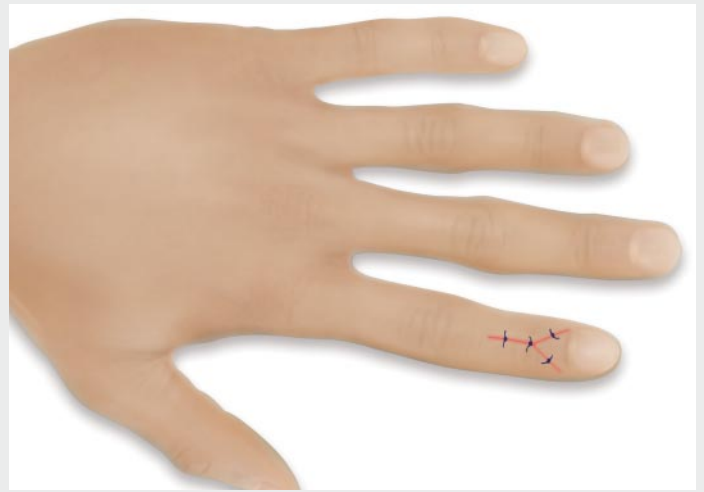
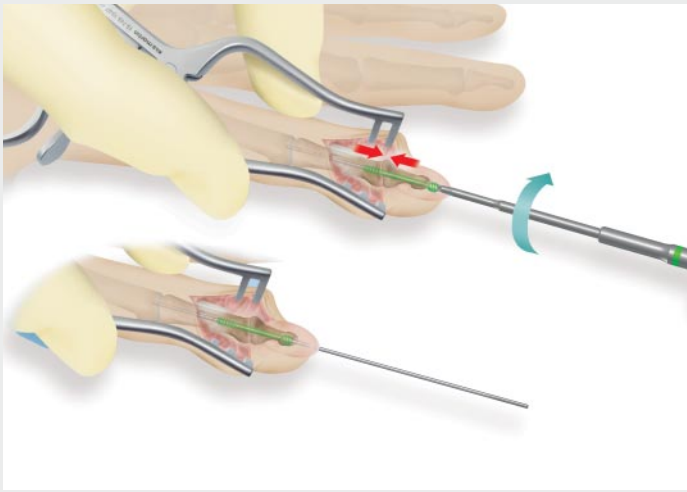
HBS 2 midi guide wire,  
double-pointed,  
Ø 0.9 mm, 120 mm



HBS 2 mini  
depth gauge



Segmented step drill



#### 6. Placement of the screw

The screw is implanted from distal via the K-wire using the screwdriver. To prevent the screw from becoming wedged against the wire, the guide wire should be retracted as soon as the distal thread has passed the articular cavity.

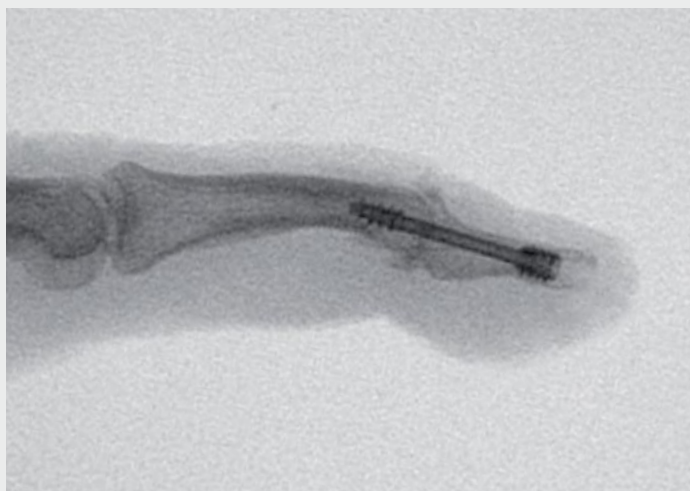
The final position of the screw should be selected in such a way that the proximal thread comes to rest slightly below the bone surface.

#### 7. Wound closure

Wound closure is performed layer by layer. Skin suture is followed by a final X-ray exposure.



HBS 2 mini  
Screwdriver T6/T7

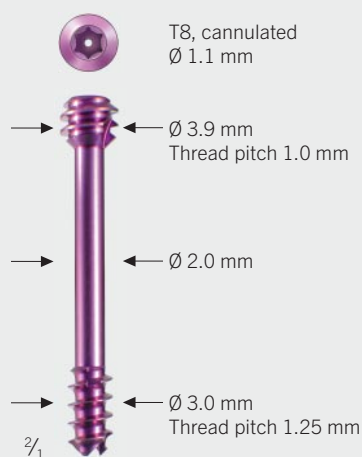


Source: Prof. Krimmer

#### **Follow-up treatment**

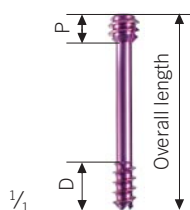
Immobilization on a plaster splint for approx. 3-5 days until confirmed wound healing, followed by the application of a postural DIP splint for 4 weeks.

## Implants, instruments and storage tray **HBS 2**



### HBS 2 midi short thread

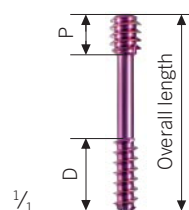
Proximal thread length  
**p = 3.5 mm**



Overall Length (mm)	Item No. non-sterile	<b>STERILE</b> ↓	Distal Thread Length D (mm)
10	26-800-10-09	26-800-10-71	4.0
11	26-800-11-09	26-800-11-71	4.0
12	26-800-12-09	26-800-12-71	4.0
13	26-800-13-09	26-800-13-71	4.0
14	26-800-14-09	26-800-14-71	5.0
15	26-800-15-09	26-800-15-71	5.0
16	26-800-16-09	26-800-16-71	5.0
17	26-800-17-09	26-800-17-71	5.0
18	26-800-18-09	26-800-18-71	5.0
19	26-800-19-09	26-800-19-71	5.0
20	26-800-20-09	26-800-20-71	5.0
21	26-800-21-09	26-800-21-71	6.0
22	26-800-22-09	26-800-22-71	6.0
23	26-800-23-09	26-800-23-71	6.0
24	26-800-24-09	26-800-24-71	6.0
25	26-800-25-09	26-800-25-71	6.0
26	26-800-26-09	26-800-26-71	6.0
27	26-800-27-09	26-800-27-71	6.0
28	26-800-28-09	26-800-28-71	6.0
29	26-800-29-09	26-800-29-71	6.0
30	26-800-30-09	26-800-30-71	6.0


### HBS 2 midi long thread

Proximal thread length  
**p = 5 mm**



Overall Length (mm)	Item No. non-sterile	<b>STERILE</b> ↓	Distal Thread Length D (mm)
20	26-810-20-09	26-810-20-71	9.0
22	26-810-22-09	26-810-22-71	9.0
24	26-810-24-09	26-810-24-71	9.0
26	26-810-26-09	26-810-26-71	10.0
28	26-810-28-09	26-810-28-71	10.0
30	26-810-30-09	26-810-30-71	11.0
32	26-810-32-09	26-810-32-71	11.0
34	26-810-34-09	26-810-34-71	12.0
36	26-810-36-09	26-810-36-71	12.0
38	26-810-38-09	26-810-38-71	12.0
40	26-810-40-09	26-810-40-71	13.0





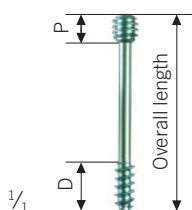
Icon explanations

- TiAl6V4
- T-Drive, cannulated
- Packing unit

**STERILE** Implants in sterile packaging

## HBS 2 mini short thread

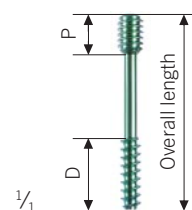
Proximal thread length  
**p = 3 mm**



Overall Length (mm)	Item No. non-sterile	<b>STERILE</b>	Distal Thread Length D (mm)
10	26-820-10-09	26-820-10-71	4.0
11	26-820-11-09	26-820-11-71	4.0
12	26-820-12-09	26-820-12-71	4.0
13	26-820-13-09	26-820-13-71	4.0
14	26-820-14-09	26-820-14-71	5.0
15	26-820-15-09	26-820-15-71	5.0
16	26-820-16-09	26-820-16-71	5.0
17	26-820-17-09	26-820-17-71	5.0
18	26-820-18-09	26-820-18-71	5.0
19	26-820-19-09	26-820-19-71	5.0
20	26-820-20-09	26-820-20-71	5.0
21	26-820-21-09	26-820-21-71	6.0
22	26-820-22-09	26-820-22-71	6.0
23	26-820-23-09	26-820-23-71	6.0
24	26-820-24-09	26-820-24-71	6.0
25	26-820-25-09	26-820-25-71	6.0
26	26-820-26-09	26-820-26-71	6.0
27	26-820-27-09	26-820-27-71	6.0
28	26-820-28-09	26-820-28-71	6.0
29	26-820-29-09	26-820-29-71	6.0
30	26-820-30-09	26-820-30-71	6.0

## HBS 2 mini long thread

Proximal thread length  
**p = 5 mm**



Overall Length (mm)	Item No. non-sterile	<b>STERILE</b>	Distal Thread Length D (mm)
20	26-830-20-09	26-830-20-71	8.0
22	26-830-22-09	26-830-22-71	9.0
24	26-830-24-09	26-830-24-71	9.0
26	26-830-26-09	26-830-26-71	10.0
28	26-830-28-09	26-830-28-71	10.0
30	26-830-30-09	26-830-30-71	11.0
32	26-830-32-09	26-830-32-71	11.0
34	26-830-34-09	26-830-34-71	12.0
36	26-830-36-09	26-830-36-71	12.0
38	26-830-38-09	26-830-38-71	12.0
40	26-830-40-09	26-830-40-71	13.0

## Instruments

### **HBS 2** midi

**HBS 2** midi  
standard instruments:



1/2

26-850-02-07  
K-wire guide  
15 cm/6"



1/2

26-850-13-07  
K-wire dispenser  
15 cm/6"  
Ø 1.1 mm



1/2

26-850-00-05  
Guide wire  
125 mm  
Ø 1.1 mm



1/2

26-850-06-07  
Depth gauge



1/2

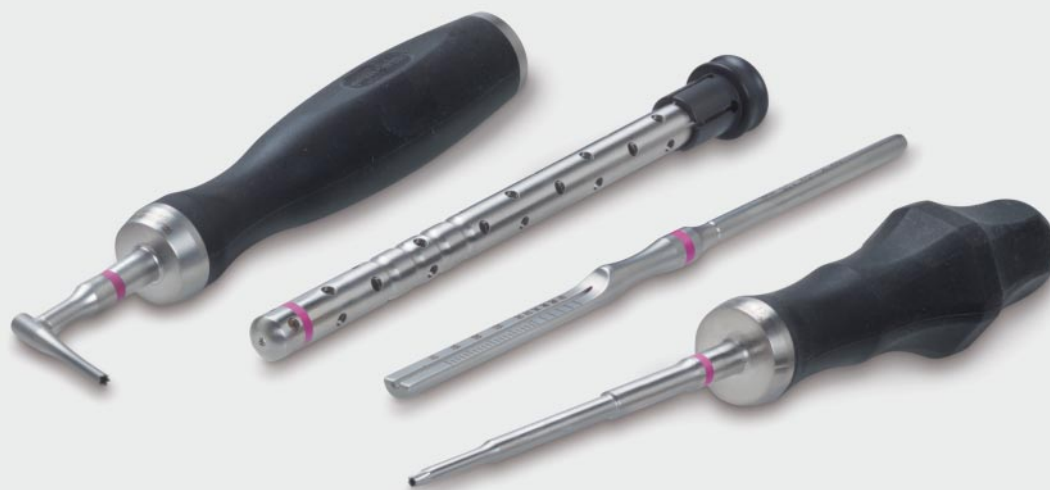26-850-17-07  
Screwdriver  
T8 cannulated








1/2

26-850-03-07  
Cleaning wire





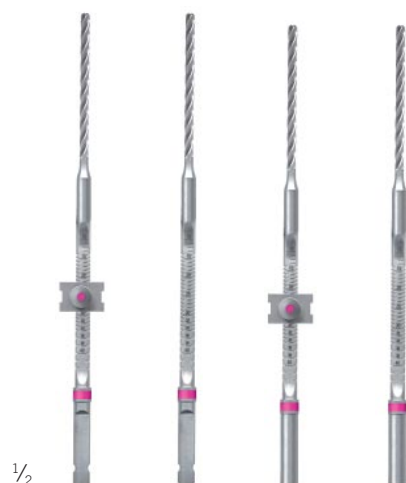#### Icon explanations

-  HBS 2 midi
-  St Steel
-  Sic Silicone
-  T-Drive, cannulated
-  1 unit(s) Packing unit

**STERILE** ↓ Implants in sterile packaging

## HBS 2 midi optional instruments:

Twist drills  
cannulated, Ø 2,3 / 1.1 mm



1/2



1/2



1/2

Attachment	non-sterile	<b>STERILE</b> ↓
<b>AO</b>		
with stop	26-850-19-09	
w/o stop	26-850-20-09	26-850-20-71
<b>cylindrical</b>		
with stop	26-850-09-09	
w/o stop	26-850-10-09	26-850-10-71

26-850-01-07  
Soft tissue sleeve



26-850-22-07  
Closing sleeve



## Instruments **HBS 2** mini

**HBS 2** mini  
standard instruments:



1/2

26-875-02-07  
K-wire guide  
15 cm/6"



1/2

26-875-13-07  
K-wire dispenser  
15 cm/6"  
Ø 0.9 mm



1/2

26-875-00-05  
Guide wire  
125 mm  
Ø 0.9 mm



1/2

26-875-06-07  
Depth gauge



1/2

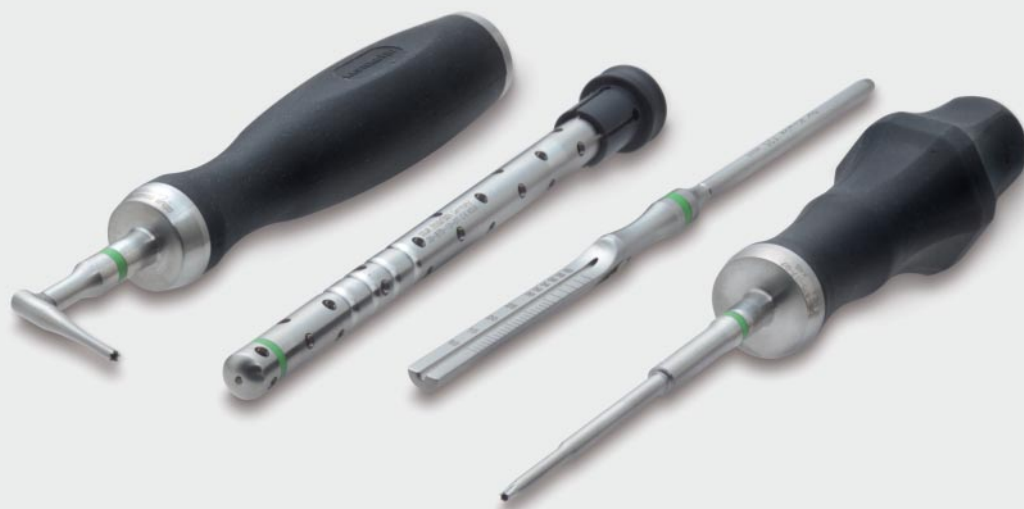26-875-17-07  
Screwdriver  
T6/T7 cannulated








1/2


26-875-03-07  
Cleaning wire





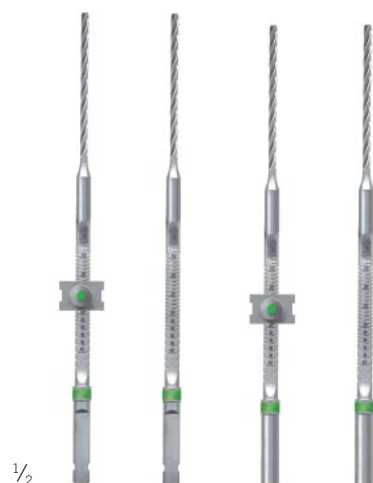#### Icon explanations

-  HBS 2 mini
-  Steel
-  Silicone
-  T-Drive, cannulated
-  Packing unit

**STERILE**  Implants in sterile packaging

## HBS 2 mini optional instruments:

Twist drills  
cannulated, Ø 1.9 / 0.9 mm



1/2

Segmented step drill  
for DIP arthrodeses,  
Ø 1.9 / 0.9 mm,  
AO attachment



1/2

Guide wire  
double-pointed  
for DIP arthrodeses,  
Ø 0.9 mm




1/2




1/2



1/2

Attachment	non-sterile	<b>STERILE</b> 
<b>AO</b>		
with stop	26-875-19-09	
w/o stop	26-875-20-09	26-875-20-71
<b>cylindrical</b>		
with stop	26-875-09-09	
w/o stop	26-875-10-09	26-875-10-71

Length	for screw	<b>STERILE</b> 
26 mm	22 mm	26-875-29-71
28 mm	24 mm	26-875-30-71
30 mm	26 mm	26-875-31-71

Length	Art. No.
60 mm	22-636-09-05
120 mm	22-637-09-05
140 mm	22-638-09-05
160 mm	22-639-09-05

26-875-01-07  
Soft tissue sleeve



26-875-22-07  
Closing sleeve



## Storage tray system

### **HBS 2** mini and **HBS 2** mini

The HBS 2 storage tray system consists of various modules.

All HBS 2 instruments that are indispensable for an operation are individually stored in the instrument insert.

Optionally available instruments – such as cannulated drill bits with different couplings, the soft tissue sleeve or the closing sleeve – can also be stored separately in the tray. In addition, there is room for free storage that can be used in line with customer needs.

The circular screw rack can hold up to 128 screws, two of each type and length. It is intended to be filled in accordance with the range of indications to be covered. When buying sterile implants the storage box for sterile implants can be ordered as an alternative to the circular screw rack. In this box 24 implants can be stored efficiently.

In addition to the standard instruments, the **HBS 2 set no. 26-800-00-04** includes an HBS 2 midi drill bit as well as an HBS 2 mini drill bit, each with stop and AO attachment, plus a selection of implants matching the special requirements of scaphoid fractures and nonunions.





Storage system		
HBS 2 midi	HBS 2 mini	
55-910-54-04		Storage tray consisting of:
		Lid, instrument insert, tray, circular screw rack

Standard instruments		
HBS 2 midi	HBS 2 mini	
26-850-02-07	26-875-02-07	K-wire guide
26-850-13-07	26-875-13-07	K-wire dispenser
26-850-00-05	26-875-00-05	Guide wire
26-850-06-07	26-875-06-07	Depth gauge
26-850-17-07	26-875-17-07	Screwdriver
26-850-03-07	26-875-03-07	Cleaning wire

Optional instruments		
HBS 2 midi	HBS 2 mini	
26-850-01-07	26-875-01-07	Soft tissue sleeve
26-850-22-07	26-875-22-07	Closing sleeve
26-850-09-09	26-875-09-09	Twist drill with stop, cannulated, cylindrical attachment
26-850-19-09	26-875-19-09	Twist drill with stop, cannulated, AO attachment
26-850-10-09	26-875-10-09	Twist drill, cannulated, cylindrical attachment
26-850-20-09	26-875-20-09	Twist drill, cannulated, AO attachment
26-850-12-07	26-875-12-07	Drill stop

Storage box for sterile implants		
55-910-53-04		Storage box made of carton (offers room for 24 implants)

## KLS Martin Group

**KLS Martin Australia Pty Ltd.**

Sydney · Australia  
Tel. +61 2 9439 5316  
australia@klsmartin.com

**KLS Martin do Brasil Ltda.**

São Paulo · Brazil  
Tel. +55 11 3554 2299  
brazil@klsmartin.com

**KLS Martin Medical (Shanghai)  
International Trading Co., Ltd.**

Shanghai · China  
Tel. +86 21 5820 6251  
china@klsmartin.com

**KLS Martin India Pvt Ltd.**

Chennai · India  
Tel. +91 44 66 442 300  
india@klsmartin.com

**Martin Italia S.r.l.**

Milan · Italy  
Tel. +39 039 605 67 31  
italia@klsmartin.com

**Nippon Martin K.K.**

Tokyo · Japan  
Tel. +81 3 3814 1431  
nippon@klsmartin.com

**KLS Martin SE Asia Sdn. Bhd.**

Penang · Malaysia  
Tel. +604 505 7838  
malaysia@klsmartin.com

**Martin Nederland/Marned B.V.**

Huizen · The Netherlands  
Tel. +31 35 523 45 38  
nederland@klsmartin.com

**Gebrüder Martin GmbH & Co. KG**

Moscow · Russia  
Tel. +7 499 792-76-19  
russia@klsmartin.com

**Gebrüder Martin GmbH & Co. KG**

Dubai · United Arab Emirates  
Tel. +971 4 454 16 55  
middleeast@klsmartin.com

**KLS Martin UK Ltd.**

London · United Kingdom  
Tel. +44 1189 000 570  
uk@klsmartin.com

**KLS Martin LP**

Jacksonville · Florida, USA  
Tel. +1 904 641 77 46  
usa@klsmartin.com

**Gebrüder Martin GmbH & Co. KG****A company of the KLS Martin Group**

KLS Martin Platz 1 · 78532 Tuttlingen · Germany  
P.O. Box 60 · 78501 Tuttlingen · Germany  
Tel. +49 7461 706-0 · Fax +49 7461 706-193  
info@klsmartin.com · www.klsmartin.com

